

Neonatal Orthoptic Screening Battery (NOSB): Four-decade Experience of Orthoptic Best Practice

Mondelli Flora^{1,2}, Barone Rita^{3,4,*}, Buscemi Andrea^{1,5-6} and Coco Marinella^{7,8}

¹*Italian Association of Orthoptists Assistants in Ophthalmology, 98039 Taormina, Italy*

²*Order of Healthcare Technicians of Medical Radiology and Technical Healthcare Professions, Rehabilitation and Prevention, 9700 Ragusa, Italy*

³*Child Neuropsychiatry – Department of Clinical and Experimental Medicine – University of Catania, 95199 Catania, Italy*

⁴*Orthoptics and Ophthalmologic Assistance school - Department of Biomedical and Biotechnological Sciences - University of Catania, 95199 Catania, Italy*

⁵*Study Center of Italian Osteopathy, 95100 Catania, Italy*

⁶*Horus Social Cooperative, 97100 Ragusa, Italy*

⁷*Department of Biomedical and Biotechnological Sciences, Section of Physiology, University of Catania, 95100 Catania, Italy*

⁸*Department of Educational Sciences, University of Catania, 95100 Catania, Italy*

Abstract: The present study describes the neonatal orthoptic screening battery (NOSB), a comprehensive orthoptic screening, based on four decades of application, aimed at early identification of signs and symptoms of ocular pathology or functional disorders. The NOSB allows for verifying the integrity of ocular components and early detection of functional alterations in ocular movements that could lead to the development of amblyopia or strabismus. The NOSB is the result of 45 years of screening activity in a primary health center assured by the National Health System in the city of Ragusa – Italy. It aims to examine and assess the neonate within the first 3 days of extrauterine life to identify visual system issues as early as possible. The NOSB may be conducted by Orthoptists, healthcare professionals specializing in neonatal and pediatric visual prevention. The Neonatal Orthoptic Screening battery (NOSB) here reported is proposed as a standard suitable for widespread adoption to be considered a "Best Practice".

Keywords: Newborn, Screening, Visual defects, Orthoptic, Best practice.

INTRODUCTION

Eye examination and vision assessment are crucial for early detection of visual defects. Through careful assessment of the ocular system, several conditions such as retinal anomalies, cataracts, glaucoma, retinoblastoma, strabismus, as well as neurological disorders and genetic syndromes, can be identified. Early detection and timely treatment of these conditions are mandatory to prevent disabling conditions related to impaired vision. Moreover, early screening of visual defects aims to improve children quality of life, also preventing visual defects which contribute to learning disorders and school performance later [1-2].

Universal eye screening involves the red reflex test for the detection of congenital cataracts and/or

glaucoma. However, screening for the red reflex solely is limited and insufficient to assess visual function and eye movements. Many issues might go unnoticed, such as eyelid ptosis, ocular muscle deficits, or signs and symptoms related to neurological problems such as the "setting sun eyes." In daily clinical practice, various tests may be applied for early detection of visual development issues [3].

Newborns and children at high risk of eye and vision problems should be referred for specialized eye and orthoptic examinations by expert healthcare professionals. This is particularly relevant for children with high prematurity, those with family histories of congenital cataracts, retinoblastoma, metabolic diseases, or genetic conditions, children with significant developmental delays and/or neurological difficulties, and children with systemic diseases associated with ocular anomalies [4]. Since children do not complain about visual difficulties, measuring visual acuity (vision screening) is an important part of routine pediatric

*Address correspondence to this author at the Child Neuropsychiatry – Department of Clinical and Experimental Medicine – University of Catania, 95199 Catania, Italy;
E-mail: rbarone@unict.it

examinations and should begin at 3 years of age. To obtain the most reliable result, the most precise and sophisticated test that the child can perform should be used [5]. In 1977, before the introduction of neonatal orthoptic screening battery (NOSB), the incidence of pediatric patients suffering from strabismus and amblyopia was 33%, according to the Social Ophthalmological Center of Ragusa in 1976. Before its introduction into the hospital, no infant received screening, and many problems of amblyopia or other ocular diseases escaped clinical attention.

This work proposes a comprehensive orthoptic screening, based on four decades of application, aimed at early identification of signs and symptoms of ocular pathology or functional disorders. This is the complete and final version of screening developed over 40 years of clinical practice.

MATERIALS AND METHODS

Currently, existing guidelines in the literature focus on eye examinations starting from 3 years of age, when the child is more cooperative, also because many ocular issues are related to cognitive difficulties and vice versa [1-2]. Guidelines also provide a broad assessment window ranging from 0 to 3 years as the initial evaluation procedure [6]. Main steps of ocular function evaluation in newborn infants are summarized in Table 1. This assessment requires active cooperation from the child in some steps, such as vision or ocular motility evaluation.

The NOSB here reported is proposed as a standard suitable for widespread adoption to be considered a "Best Practice". It aims to examine and assess the neonate within the first 3 days of extrauterine life to identify visual system issues as early as possible. The NOSB (Table 2), is the result of 45 years of screening activity in a primary health center assured by the National Health System in the city of Ragusa – Italy [7-9].

Table 1: Newborn Infant Ocular Evaluation

Family and neonatal/child ocular history
Vision assessment
Eye and eyelid inspection
Ocular motility evaluation
Pupil examination
Red reflex

Table 2: Proposed Comprehensive Orthoptic Screening (NOSB)

1. Observation
2. Spontaneous eyelid opening
3. Doll's eye movement reflex
4. Oculo-palpebral or nose-palpebral reflex (glabellar reflex)
5. Fixation reflex
6. Pupillary photomotor reflex
7. Red reflex

1. Observation involves understanding the suitability of the screening moment by observing the baby's spontaneous behavior, such as crying or quietness, facial expressions, or limb motor activity, to ensure that the baby does not have immediate nutritional or physiological needs that could affect the examination.

2. Spontaneous Eyelid Opening should be assessed by observing spontaneous behavior while responding to newborn needs. The presence of any epicanthal or epiblepharon folds should be considered, as these can be misleading and are not actually a problem. This test may also take several minutes of waiting and aims to rule out anomalies such as eyelid ptosis and asymmetry of eyelid opening, which could indicate a potential syndrome [3, 6, 10-11].

3. Doll's Eye Movement Reflex. The doll's eye reflex, also known as the oculo-vestibular reflex or oculo-cephalic reflex, mediated by vestibular nuclei, allows maintaining gaze fixation while turning the head, resulting in a conjugate lateral deviation of the eyeballs in the opposite direction to head rotation. This maneuver demonstrates the integrity of brainstem structures (oculogyric functions and cranial nerve nuclei). To check for absence of deficits in horizontal ocular muscles, it is important to turn the head to the right and left, ensuring that the eyes reach the extreme gaze position [12-13].

4. Glabellar Reflex. The glabellar reflex is a primitive and physiological reflex in newborns, causing contraction of the orbicularis oculi muscle and evoked by tapping on the glabella. Gently pressing the root of the nose causes the newborn to blink. This reflex stimulates the ophthalmic branch (V1) of the trigeminal nerve (Cranial Nerve V). This is a neonatal primitive reflex, normally present until six months of age; its

absence might suggest delayed maturation or impairment of the neurologic circuits related to Cranial Nerves V and VII.

5. Pupillary or Photomotor Reflex. The pupillary reflex, or photomotor reflex, is the pupillary response to light stimulation (pupillary reflex to light). Light causes miosis (direct photomotor reflex) in the stimulated eye and simultaneous miosis (indirect and consensual photomotor reflex) in the contralateral eye. This reaction presupposes the integrity of the reflex arc and occurs with typical reflex characteristics (unidirectional impulse conduction, central conduction time, susceptibility to hypoxia, anesthetics, emotional states, etc.). The reflex evaluation should be conducted in low ambient lighting conditions. If the pupil fails to constrict with light stimulation, a neurological issue should be suspected. In detail, the pupillary reflex pathway involves 4 types of neurons in succession: a) Retinal ganglion cells, which transmit information from photoreceptors to the optic nerve. This reaches the pretectal nucleus in the superior midbrain. b) A second neuron from the pretectal nucleus reaches the Edinger-Westphal nucleus. c) A third neuron originates from the Edinger-Westphal nucleus and forms the ipsi- and contralateral oculomotor nerves, which reach the ciliary ganglia. d) Finally, a fourth neuron forms the short

ciliary nerve, which innervates the pupillary constrictor muscle [14-15].

6. Fixation and Visual Engagement Reflex. This reflex is part of primary visual skills. To evoke it, it is necessary to wait until the newborn is not bothered by hunger or external factors and to attract visual attention by creating "visual engagement." In a newborn of a few days, this visual engagement will last a few seconds. To attract more attention, facets of Fantz or high-contrast concentric circles (e.g., black/white) can be used. Involuntary ocular fixation movement is crucial to project an object's image onto the fovea. The absence of this reflex might suggest immaturity of the visual system, requiring continued stimulation and orthoptic exercises until maturation and motor learning are achieved.

The visual intervention consists of black and white stimulation cards that aim to stimulate vision through engagement, fixation and tracking exercises (Figure 1).

The newborn's focal range, about 19 cm, should also be considered when presenting visual stimuli to avoid skewing the test [16].

7. Red Reflex. The red reflex is the appearance of a red coloration across the entire pupillary field when the



Figure 1: Engagement, fixation and tracking exercises.

eye is illuminated with an ophthalmoscope. It is performed by shining a light beam onto the eye being examined using a direct or indirect ophthalmoscope (not a simple flashlight) at an approximate distance of 30-50 centimeters, while maintaining as much as possible the coaxial gaze with the light beam. The red reflex should appear uniformly red across the entire pupillary surface, with consistent coloration, intensity, and clarity, and should not show any more or less extensive opacities. Although the neonatal pathology being sought has a low prevalence (0.1-1.5/1000 for congenital cataracts; 0.1-0.3/1000 for glaucoma; 0.04-0.8/1000 for iris coloboma), experiences from various healthcare centers suggest that the values increase significantly among children from foreigners. Additionally, it is highly useful for providing information about the visual system and increasing awareness among users (healthcare practitioners and parents) [17].

DISCUSSION

Ocular examination and vision assessment are vital for identifying conditions that can lead to blindness, indicate serious systemic disease, result in school performance problems, or even threaten a child's life. Through careful assessment of the ocular system, retinal anomalies, cataracts, glaucoma, retinoblastoma, strabismus, and neurological disorders can be identified. Timely diagnosis and treatment of eye disorders in children are important to avoid permanent visual deficits [18]. All children should benefit from vision problem assessments starting in the neonatal period and during subsequent check-ups. These assessments should be age-appropriate. With the described neonatal orthoptic screening, it is possible to detect visual function disorders such as abduction

deficits, convergence spasms, and setting sun eyes within the first days of extrauterine life. These issues might be linked to visual system immaturity and can be resolved through appropriate orthoptic stimulation and exercises [19]. Similarly, early identification of these issues allows the healthcare team to monitor the newborn and intervene promptly if these dysfunctions indicate a neurological clinical problem, such as hydrocephalus or Down syndrome. The described orthoptic screening is simple, non-invasive, and provides a comprehensive assessment for identifying and evaluating neonatal visual function. If the test reveals signs indicative of eye pathology, the orthoptist will refer the newborn to an ophthalmologist for appropriate care, ensuring an early diagnosis and treatment. For example, in the case of congenital cataracts or hydrocephalus, identifying the issue on the first days of life allows for immediate intervention, solving the problem and allowing proper development of visual function in its entirety, avoiding cognitive, motor, and postural repercussions [20]. Neonatal orthoptic screening is a valuable tool that provides a simple, comprehensive evaluation, enabling the orthoptist to standardize neonatal examinations and gain confidence and speed in identifying both physiological issues related to visual system immaturity and those associated with pathology [6-7]. A healthcare system that employs a rapid visual problem identification tool will be better equipped to provide timely care, reducing costs associated with delayed diagnoses. Additionally, young patients will benefit from early intervention, and problem resolution will ensure normal development of visual, cognitive, and motor functions. Identifying visual function deficits allows for early information to caregivers and the initiation of visual health education, which can even start during pregnancy through childbirth support courses for

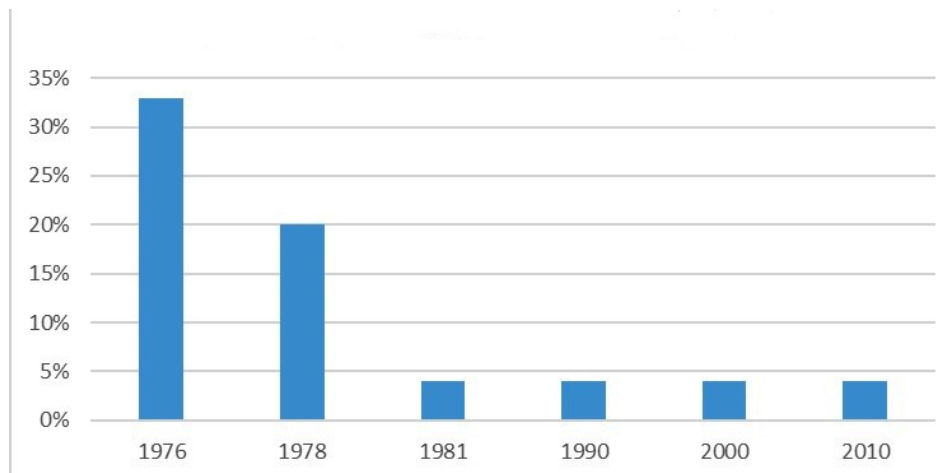


Figure 2: Amblyopia incidence among pediatric patients, before and after the adoption of the NOSB in the city of Ragusa (Italy).

expectant mothers. Neonatal orthoptic screening was introduced by one of the Author (FM) in the neonatology department of the Civil Hospital of Ragusa in 1977 with the goal of reducing the incidence of pediatric patients with strabismus and amblyopia (33% according to the Social Ophthalmology Center of Ragusa in 1976).

Neonatal orthoptic screening was introduced by one of the Authors (FM) in the neonatology department of the Civil Hospital of Ragusa in 1977 with the goal of reducing the incidence of pediatric patients with strabismus and amblyopia (33% according to the Social Ophthalmology Center of Ragusa in 1976).

By 1981, the percentage had dropped to 4%, placing it within national standards (Figure 2). Early assessment of visual function has allowed for the identification of not only visual deficits that could lead to strabismus and amblyopia, but also signs of ocular and neurological pathology.

COSTS AND STRATEGIC COMPROMISES

Assigning the administration of NOSB to orthoptists would be a valid strategy in terms of reliable results and costs for the healthcare system. Orthoptists, as healthcare professionals trained in Orthoptics and Ophthalmic Assistance, are specifically trained in the field of "Orthoptics" and are thus the reference figure for visual function evaluation. Furthermore, orthoptists receive compensation in the "non-managerial healthcare personnel" sector rather than "management," resulting in cost reduction [21-22].

LIMITATIONS

A limitation to the application of this screening is that the results depend on the operator; therefore, the more trained and experienced the professional administering is, the more reliable the results will be. We recommend initial training and periodic refresher training to evaluate and monitor sector operators over time. This issue was extensively addressed in the 1990s by Brazelton and Nugent, who recommended specific initial training and periodic theoretical-practical training reminders to avoid routine test habituation, which could lead to errors and also suggested informative training for caregivers [23-24]. The training must be given to the caregiver as soon as the visual problem is detected and repeated after 4 months and 8 months. Orthotists and medical doctors should repeat the training every two years.

CONCLUSIONS

The NOSB is easy to implement, non-invasive, and allows for the detection of visual function issues from the first day of birth. It would be ideal to apply it within the first three days after birth, as newborns in a hospital setting would not escape clinical observation, a problem that could arise in an outpatient management post-discharge. Currently, in Italy, the Universal Ocular Screening mandated by the Prime Minister's Decree of January 12, 2017, only involves the red reflex test and can be administered by ophthalmologists, pediatricians, and adequately trained healthcare personnel [25]. From the literature, it is evident that the most appropriate healthcare operator to perform these tests is the Orthoptist, who can be integrated into the non-managerial staff of pediatric units with birthing centers, thereby significantly reducing long-term healthcare costs resulting from false negatives and operator errors [26]. The NOSB allows for verifying the integrity of ocular components and early detection of functional alterations in ocular movement balance that could lead to the development of amblyopia or strabismus [27].

Therefore, neonatal orthoptic screening allows for the identification of anomalies or their causes before they become irreversible. The screening is conducted by Orthoptists, healthcare professionals specializing in neonatal and pediatric visual prevention [26]. Ultimately, introducing the profession of Orthoptist would allow for sensitizing, informing, and training future parents in proper visual stimulation, playing an important role in caregiver education through childbirth support courses.

CONFLICTS OF INTEREST

The authors declare no conflicts of interest.

REFERENCES

- [1] Committee on Practice and Ambulatory Medicine Section on Ophthalmology *et al.* "Eye examination in infants, children, and young adults by pediatricians: organizational principles to guide and define the child health care system and/or improve the health of all children." *Ophthalmology* 2003; 110(4): 860-5. [https://doi.org/10.1016/S0161-6420\(03\)00414-7](https://doi.org/10.1016/S0161-6420(03)00414-7)
- [2] Committee on Practice and Ambulatory Medicine, Section on Ophthalmology. American Association of Certified Orthoptists *et al.* "Eye examination in infants, children, and young adults by pediatricians." *Pediatrics* vol. 111,4 Pt 1 (2003): 902-7. <https://doi.org/10.1542/peds.111.4.902>
- [3] Holmes, Jonathan M, and Michael P Clarke. "Amblyopia." *Lancet* (London, England) vol. 367, 9519 (2006): 1343-51. [https://doi.org/10.1016/S0140-6736\(06\)68581-4](https://doi.org/10.1016/S0140-6736(06)68581-4)
- [4] Wright, K. W., Spiegel, P. H. & Hengst, T. *Pediatric Ophthalmology and Strabismus* (Springer, 2013).

- [5] Long E, Lin Z, Chen J, Liu Z, Cao Q, Lin H, Chen W, Liu Y. Monitoring and Morphologic Classification of Pediatric Cataract Using Slit-Lamp-Adapted Photography. *Transl Vis Sci Technol.* 2017 Nov 2; 6(6): 2. <https://doi.org/10.1167/tvst.6.6.2>
- [6] Rossi A, Gnesi M, Montomoli C, Chirico G, Malerba L, Merabet LB; NAVeG Study Group; Fazzi E. Neonatal Assessment Visual European Grid (NAVeG): Unveiling neurological risk. *Infant Behav Dev.* 2017 Nov; 49: 21-30. <https://doi.org/10.1016/j.infbeh.2017.06.002>
- [7] Mondelli F. - Prevenzione oculare dalla nascita all'età prescolare - *Prisma*, 1999; 3: 5-7
- [8] Mondelli F. - Elementi di screening ortottico neonatale - AA. Vari - Guida alla professione di ortottista - capitolo 6, 485-497 2009, ISBN 998-88-7351-268-4
- [9] Mondelli F. - Prevenzione visiva: piano di lavoro per gli Ortottisti - *Prisma* 2012; 2: 5-7.
- [10] Artusio V. Ruolo dell'ortottista all'interno del reparto di neonatologia: screening ortottico neonatale. *Prisma* 2019; 1: 8-13.
- [11] Wu P, Ma J, Zhang T, Ma D. Advances in the Genetics of Congenital Ptosis. *Ophthalmic Res.* 2022; 65(2): 131-139. <https://doi.org/10.1159/000521575>
- [12] Zegeer LJ. Oculocephalic and vestibulo-ocular responses: significance for nursing care. *J Neurosci Nurs.* 1989 Feb; 21(1): 46-55. <https://doi.org/10.1097/01376517-198902000-00009>
- [13] Snir M, Hasanreisoglu M, Goldenberg-Cohen N, Friling R, Katz K, Nachum Y, Benjamini Y, Herscovici Z, Axer-Siegel R. Suppression of the oculocephalic reflex (doll's eyes phenomenon) in normal full-term babies. *Curr Eye Res.* 2010 May; 35(5): 370-4. <https://doi.org/10.3109/02713680903576708>
- [14] Pinheiro HM, da Costa RM. Pupillary light reflex as a diagnostic aid from computational viewpoint: A systematic literature review. *J Biomed Inform.* 2021 May; 117: 103757. <https://doi.org/10.1016/j.jbi.2021.103757>
- [15] Kardon, R. "Pupillary light reflex." *Current opinion in ophthalmology* 1995; 6(6): 20-6. <https://doi.org/10.1097/00055735-199512000-00004>
- [16] Derricksen, 2006 - Principi di anatomia e fisiologia. CEA, 2011. EAN: 9788808182326. ISBN: 8808182320
- [17] American Academy of Pediatrics *et al.* "Red reflex examination in neonates, infants, and children." *Pediatrics* 2008; 122(6): 1401-4. <https://doi.org/10.1542/peds.2008-2624>
- [18] Lam, Matthew, and Donny Suh. "Screening, Diagnosis, and Treatment of Pediatric Ocular Diseases." *Children* (Basel, Switzerland) vol. 9,12 1939. 10 Dec. 2022 <https://doi.org/10.3390/children9121939>
- [19] Mondelli F., Fresta R., Zasa A. Prevenzione ortottica in neonatologia - G.I.O., 2018, 10, 55-60; ISSN1973-5170
- [20] Stjerna S, Sairanen V, Gröhn R, Andersson S, Metsäranta M, Lano A, Vanhatalo S. Visual fixation in human newborns correlates with extensive white matter networks and predicts long-term neurocognitive development. *J Neurosci.* 2015 Mar 25; 35(12): 4824-9. <https://doi.org/10.1523/JNEUROSCI.5162-14.2015>
- [21] Buscema D, Campo C., Mondelli F., Pavone G., Spampinato R. Dépistage oftalmologico neonatale limiti e possibilità. *Giornale Italiano d'Ortottica (e Tecnica Sperimentale Oftalmica).* 1981; 8: 147-150. ISSN 0390-279X
- [22] Contratto Collettivo Nazionale di Lavoro relativo al personale del comparto sanità triennio2019-2021. 31/03/2023. <https://www.aranagenzia.it/contrattazione/comparti/comparto-della-sanita/contratti.html>
- [23] Brazelton T.B., Nugent J.K.; La scala di valutazione del comportamento del neonato, Masson et Cie. Milano 1997.
- [24] Beeghly, M *et al.* "Specificity of preventative pediatric intervention effects in early infancy." *Journal of developmental and behavioral pediatrics* : JDBP 1995; 16(3): 158-66. <https://doi.org/10.1097/00004703-199506000-00003>
- [25] Decreto del presidente del consiglio dei ministri 12 gennaio 2017, *Gazzetta Ufficiale Serie Generale*, n. 65 del 18 marzo 2017
- [26] Bolger, P G *et al.* "Vision screening in preschool children: comparison of orthoptists and clinical medical officers as primary screeners." *BMJ (Clinical research ed.)* 1991; 303(6813): 1291-4. <https://doi.org/10.1136/bmj.303.6813.1291>
- [27] Moran CA, Costa VSLP, Marx LO, Fernandes Costa M. Visual stimulation in the neonatal intensive care unit: A systematic literature review. *J Child Health Care.* 2024 Jan 11:13674935241227344. Epub ahead of print. PMID: 38213009. <https://doi.org/10.1177/13674935241227344>

Received on 12-01-2024

Accepted on 15-02-2024

Published on 27-02-2024

DOI: <https://doi.org/10.12974/2311-8687.2024.12.02>© 2024 Mondelli *et al.*

This is an open access article licensed under the terms of the Creative Commons Attribution Non-Commercial License (<http://creativecommons.org/licenses/by-nc/3.0/>) which permits unrestricted, non-commercial use, distribution and reproduction in any medium, provided the work is properly cited.